

## SEGMENTAL ANOMALIES IN *RONCUS* AFF. *LUBRICUS* (NEOBISIIDAE, PSEUDOSCORPIONES) FROM YUGOSLAVIA

**B. P. M. Ćurčić, R. N. Dimitrijević, O. S. Karamata, and L. R. Lučić:** Institute of Zoology, Faculty of Science, University of Belgrade, 16, Studentski Trg, YU-11000 Beograd, Yugoslavia.

**ABSTRACT.** Malformations in the abdominal segmentation patterns were studied in two pseudoscorpion species of the genus *Roncus* L. Koch, inhabiting Yugoslavia. A total of 36 abnormal examples were found out of 4,825 specimens examined. All anomalous pseudoscorpions were dissected and subjected to the pathomorphological analysis. The frequency of the aberrant specimens was variable, depending on the locality, growth stage, sex, and species. The following malformations were noted: hemimery; partial atrophy (single and multiple); symphysomery (single and multiple); and combinations of different anomalies (combined hemimery and sclerite enlargement; combined hemimery and symphysomery; combined partial atrophy and symphysomery; combined partial atrophy and sclerite enlargement; combined atrophy or hemimery, symphysomery and sclerite enlargement; combined atrophy, symphysomery, helicomery and sclerite enlargement; and combined atrophy, helicomery and sclerite enlargement). Teratological variation of the abdominal sclerites has been confined mostly to adults and, to a lesser degree, to tritonymphs. In addition, some specific features of the relative distribution of various segmental deficiencies are considered. Finally, the probable causes of the genesis and development of segmental anomalies in the pseudoscorpions studied have been also discussed.

Developmental anomalies are known to occur in pseudoscorpions, the most common being the malformations of various abdominal sclerites (Legg and Jones 1988; Ćurčić 1989a, b). Aberrations may be produced internally or externally, the latter being induced mechanically, chemically or physically. Internally induced aberrations occur during development (including the molting period). These malformations were first noted by With (1905), Kästner (1927) and Hadži (1937), and later classified by Gilbert (1952) and Pedder (1965). More recently, Ćurčić (1980, 1988, 1989a, b), Ćurčić and Dimitrijević (1982, 1984, 1986), Ćurčić et al. (1981, 1983), and Dimitrijević (1985, 1990) have provided further examples and attempted to quantify the phenomenon.

In the majority of the species studied, the deformities of the abdominal sclerites were confined to the tritonymph/adult, or maturation molt. Aberrations were thought to represent post-embryonic molt phenomena (Pedder 1965) but their origin and development are still not sufficiently understood at this moment. In *Neobisium carpaticum* Beier, Ćurčić (1989a, b) and Ćurčić and Dimitrijević (1982) found a teratological incidence of 1.4% out of 1,300 specimens examined; and in *N. sylvaticum* (C. L. Koch) the incidence was 2%. The majority of deficiencies

occurred at the maturation molt and were confined mostly to males.

Teratological deformities, although not entirely restricted to individuals undergoing the maturation molt, occur most commonly at that time. Such variations include alterations of segmentation and change in structure of appendages (Weygoldt 1969), tergal/sternal abnormalities, variation in surface sculpturing and setal and trichobothrial distribution patterns. In some cases the abnormalities found in adults represent the retention of tritonymphal features, or localized neoteny (Gupta 1979; Gabbutt and Vachon 1963; Weygoldt 1969). It is supposed that a slight disruption of the neurosecretory and endocrine system or local variations in the interpretation of the neurosecretions could lead to localized teratological abnormalities.

Among the Cheliferinea, abdominal malformations have been described in *Ellingsenius sculpturatus* (Lewis), *Anatemnus javanus* (Thorell), *Dactylochelifera latreillei* (Leach), *Synsphyronus mimetus* Chamberlin, *Horus granulatus* (Ellingsen), *Allochernes wideri* (C. L. Koch), *Lamprochernes nodosus* (Schrank) and *Allochernes dubius* (O. P.-Cambridge) (With 1905; Hadži 1930; Gilbert 1952; Chamberlin 1949; Beier 1955; Weygoldt 1969; Pedder 1965).

In the Chthoniinea, a number of segmental

anomalies have been recorded from *Chthonius tenuis* (L. Koch), *C. aff. tetrachelatus* (Preysslner) and *C. ischnocheles* (Hermann) (Pedder 1965; Dimitrijević 1990).

Among the Neobisiinea, false scorpions have been found with segmentation deficiencies involving the dorsal and ventral sclerites. Such aberrations have been noted in *Neobisium erythro-dactylum* (L. Koch), *N. maritimum* (Leach) and *N. muscorum* (Leach) (Pedder 1965). Only recently, comparative aspects of teratological variation have been studied in other neobisiid species: *N. carpaticum*, *N. macrodactylum* (Daday), *N. cephalonicum* (Daday), *N. sylvaticum*, *N. fuscimanum* (C. L. Koch) (Čurčić 1980; Čurčić and Dimitrijević 1982, 1984, 1985, 1986; Čurčić et al. 1983), *N. bernardi* Vachon and *N. simoni* (L. Koch) (Dimitrijević 1990). These studies have revealed the heterogeneity of segmental anomalies affecting abdominal sclerites. Such variations include fusion, splitting and loss of tergites and sternites. In addition, different combinations of these anomalies may be present in a single pseudoscorpion specimen (Čurčić 1989a, b).

Quantitative and qualitative analysis of different samples of the genus *Roncus* L. Koch revealed aberrations (anomalies) in the chelicerae, pedipalps and abdomen but not in the walking legs and the cephalothorax. Thus in *R. lubricus* L. Koch, 1873, from Mt. Avala, near Belgrade, Yugoslavia two or three teeth often grow (fuse) together on both fingers of the pedipalpal chelae. Furthermore, Čurčić (1980) noted an anomaly in the sclerite segmentation, which was manifested in the fusion of tergites III–VI on each side and in partial fusion of tergites VIII and IX of the same specimen. Similar cases of sternal anomalies have been recorded in the same species by Čurčić and Dimitrijević (1984), where the phenomena of sclerite fusion (symphysomery), atrophy and enlargement have been noted. As a consequence of these anomalies, some parts of the aberrant sternites lack its normal setae. Out of four other aberrant specimens (males and females) (Čurčić and Dimitrijević 1984; Dimitrijević 1985), multiple tergal atrophy was noticed in three specimens, while symphysomery was observed in only one specimen. The atrophy occurred on both anterior and posterior tergites and symphysomery on more posterior tergites. The percentage of aberrant specimens from these samples ranged from 0.46% to 0.95% (Čurčić and Dimitrijević 1986; Dimitrijević 1985). Čurčić and Dimitrijević (1988) provided further evidence of

sclerite anomalies in *R. lubricus* from Mt. Avala II. In the sample studied, different abdominal malformations were found in 0.67% of all specimens, the ratio of aberrant males to females being 4:1. The following anomalies were noted: partial atrophy, hemimery, (single) symphysomery, and a combination of partial atrophy and tergite enlargement (Čurčić 1989b). As a consequence of these aberrations, setal counts and disposition were altered.

Anomalies in different body structures have also been observed in some cavernicolous species of *Roncus* inhabiting underground habitats of the Dinaric Karst (Čurčić 1988). Thus, in a male of *R. pripegala* Čurčić, the trichobothriotaxy of one movable chelal finger was altered (5 trichobothria instead of 4). In another pseudoscorpion, *R. aff. stussineri* (Simon), a symphysomery of sternites VII and VIII was found, while in *R. timacensis* Čurčić and *R. remesianensis* Čurčić, there were also aberrations in the structure of the chelicerae, in the chelical setation, and in the structure of the chelal teeth (Čurčić 1983).

The primary purpose of this study was to analyze the quantitative and qualitative variations of abdominal anomalies in two Yugoslavian species of *Roncus* pseudoscorpions, their frequencies, common occurrences, and the possible factors affecting their development and distribution.

#### MATERIAL AND METHODS

We have analyzed the accidental and teratological variation of abdominal deficiencies in a population sample of *R. aff. lubricus* (sample A) from the village of Obrež, near Belgrade, Yugoslavia, as well as in samples of *R. aff. lubricus* (sample B) from the village of Asanovac and from the village of Dubova (Ravnište), both near Žitoradja, Yugoslavia. The numbers of specimens collected in these localities are presented in Table 2.

Samples of the two pseudoscorpion species studied were obtained by sifting oak leaf litter and humus over a period from April 1989 to September 1990 (Obrež sample) and from January 1989 to May 1989 (Asanovac and Dubova samples). Samples were taken once a month at each of the two localities.

After dissection, all specimens were mounted in gum chloral medium (Swan's fluid) and examined carefully. The terminology for segmental anomalies in this study is the same as used for other arthropods (Balazuc 1948, 1967). This ter-

Table 1.—Frequency of different anomalies in *Roncus* aff. *lubricus* (A) and (B) (expressed as a percentage of the total number of anomalies noted in each particular species sample). OBR = Obrež, ASA = Asanovac, DUB = Dubova.

Segmental anomaly	Species/locality		
	(A) OBR	(B) ASA	(B) DUB
Hemimery	4	—	—
Partial atrophy			
single	—	17	28
multiple	4	—	—
Symphysomery			
single	21	—	44
multiple	4	—	—
Combined hemimery and sclerite enlargement	25	49	28
Combined hemimery and symphysomery	—	17	—
Combined partial atrophy and symphysomery	8	—	—
Combined partial atrophy and sclerite enlargement	13	—	—
Combined (single or multiple) symphysomery and sclerite enlargement	—	17	—
Combined atrophy (or hemimery), symphysomery and sclerite enlargement	13	—	—
Combined atrophy, symphysomery, helicomery and sclerite enlargement	4	—	—
Combined atrophy, helicomery and sclerite enlargement	4	—	—
Total	100	100	100

minology has been somewhat modified by Čurčić and Dimitrijević (1986) and Čurčić (1989a, b) to include the whole range of sternal and tergal deficiencies which were observed in pseudoscorpions.

The false scorpions analyzed for the present study belong to the *R. lubricus* species complex. The two samples (A and B) are close to *R. lubricus* [see Gardini (1983) for description of the male lectotype from the United Kingdom] but differ both from *lubricus* (*sensu stricto*) and from each other in many important respects. It therefore seems that they belong to two new, previously undescribed specific taxa. Since their precise taxonomic status is considered elsewhere

(Čurčić, Dimitrijević & Karamata, in prep.) these two relevant species have been designated as *R. aff. lubricus* (A) and (B). A chi-square test was used to verify the assumption of the possible sex-linked inheritance of the abdominal deficiencies in the analyzed species.

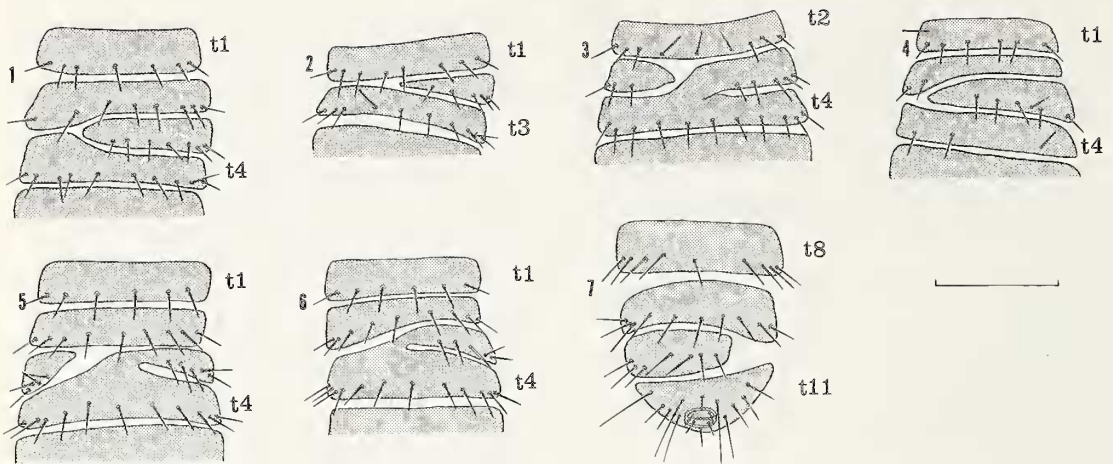
RESULTS

There was a total of 36 abnormal specimens [23 of *R. aff. lubricus* (A) and 13 of *R. aff. lubricus* (B)] (Table 3). Analysis of teratological variation of segmental anomalies in the pseudoscorpions studied gave the following results:

*Roncus* aff. *lubricus* (A)

Table 2.—The number of specimens of *Roncus* aff. *lubricus* (A) and (B) (by sex and growth stages) collected from various sites. M = males, F = females, T = tritonymphs, D = deutonymphs, P = protonymphs, OBR = Obrež, ASA = Asanovac, DUB = Dubova.

Species	Site	Sex/instar					Total
		M	F	T	D	P	
<i>R. aff. lubricus</i> (A)	OBR	1335	832	883	34	—	3084
<i>R. aff. lubricus</i> (B)	ASA	512	433	237	—	—	1182
<i>R. aff. lubricus</i> (B)	DUB	242	225	91	1	—	559
Total		2089	1490	1211	35	—	4825



Figures 1-7.—*Roncus* aff. *lubricus* (A) from Obrež, near Belgrade, Yugoslavia. Scale line = 0.5 mm. 1. - tergites I-IV, female; 2. - tergites I-III, female; 3.- tergites II-IV, female; 4. - tergites I-IV, female; 5. - tergites I-IV, female; 6. - tergites I-IV, female; 7. - tergites VIII-XI, female.

**Village of Obrež.** – Female (Fig. 1). A section of tergite III is missing on the left. As a consequence, the left parts of tergites II and IV are enlarged to fill the missing part of tergite III; the setation of this tergite is altered. **Hemimery** and **tergite enlargement**.

Female (Fig. 2). The left part of tergite II is completely missing, and the setae are unequally distributed. **Hemimery**.

Female (Fig. 3). The right part of tergite III is fused with the anterior mid-region of tergite IV. A small section of tergite III is present on the left. The number and disposition of setae on tergite III are altered as a consequence of this anomaly. **Partial helicomery**, **atrophy** and **tergite enlargement**.

Female (Fig. 4). A small part of tergite III is missing on the left. Tergite II is enlarged and fills the space where the missing part of tergite III would otherwise be found. The setae on tergite II are almost all missing, and their position on tergites III and IV is changed. **Atrophy** and **tergite enlargement**.

Female (Fig. 5). Right part of tergite III is fused with tergite IV medially. A small part of tergite III is isolated on the left and the median region of this tergite lacks setae. **Partial atrophy** and **symplysomery**.

Female (Fig. 6). The left part of tergite III is missing, and the remaining part of this sclerite is fused with the mid-anterior region of tergite IV. Tergites II and IV are enlarged to fill the space left vacant in tergite III. The setae on tergite III

are missing in part. **Atrophy** (possibly **hemimery**), **symplysomery** and **tergite enlargement**.

Female (Fig. 7). Tergite X is reduced on the right, and its number of setae is smaller than in normal specimens. The right posterior and lateral part of tergite IX is enlarged to fill part of the space where the missing part of tergite X would otherwise be found. **Hemimery** and **tergite enlargement**.

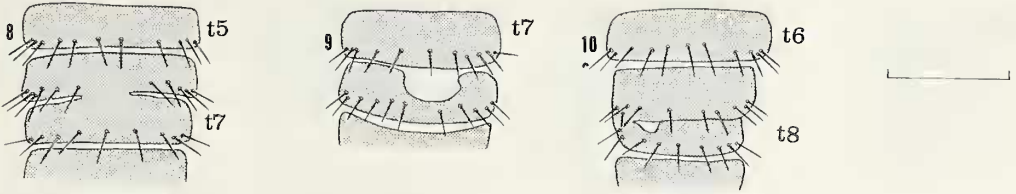
Female (Fig. 8). Tergite VI is fused with tergite VII medially. As a result of this anomaly, the disposition of setae on tergite VI is altered. **Symplysomery**.

Female (Fig. 9). The mid-anterior part of tergite VIII is lacking. The posterior border of the preceding tergite is slightly enlarged posteriorly. **Partial atrophy** and **tergite enlargement**.

Female (Fig. 10). Tergites VII and VIII are fused on the left; in addition, a small part of tergite VIII is missing on the left. **Partial atrophy** and **symplysomery**.

Male (Fig. 11). Tergites III and IV are fused medially and on the right. A small isolated section of tergite III with 3 setae is present on the right. The mid-region of tergite III is devoid of setae. In addition, tergite II is slightly enlarged posteriorly. **Symplysomery**, **atrophy** and **tergite enlargement**.

Male (Fig. 12). The left part of tergite IV is missing, and the following tergite is enlarged on the left to fill the space left vacant by tergite IV, hence the irregular setation on tergites IV and V. **Hemimery** and **tergite enlargement**.



Figures 8-10.—*Roncus* aff. *lubricus* (A), from Obrež, near Belgrade, Yugoslavia. Scale line = 0.5 mm. 8. - tergites V-VII, female; 9. - tergites VII, VIII, female; 10. - tergites VI-VIII, female.

Male (Fig. 13). The abnormalities affect five tergites. First, tergite II is atrophied on the left and tergite III is enlarged to fill the space where the missing part of tergite II would otherwise be found. Second, tergites IV-VI are fused on the left. As a result of this anomaly, the number of setae on tergites II-V is reduced, and their distribution is altered when compared with normal specimens. **Atrophy, hemimery, tergite enlargement and multiple symphysomery.**

Male (Fig. 14). The right part of tergite II is completely lacking, and the setae are unequally distributed. Tergite III is enlarged to fill the space left vacant in tergite II. **Hemimery and tergite enlargement.**

Male (Fig. 15). Tergites II and III are fused on the left, hence the irregular setation of tergite II. **Symphysomery.**

Male (Fig. 16). The malformations affect three tergites. The mid-region and right part of tergite VI are weakly sclerotized, and its distribution of setae is irregular (two setal rows on the right part of the sclerite). Furthermore, small sections of

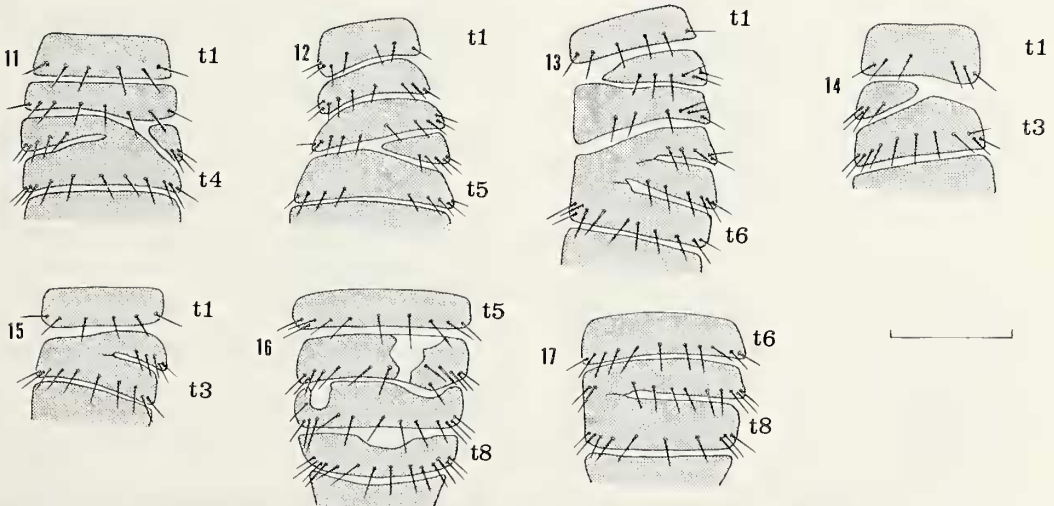
tergite VII (on the left) and tergite VIII (on the anterior border) are missing. **Multiple (partial) atrophy.**

Male (Fig. 17). Tergites VII and VIII are fused on the left, hence the irregular distribution of setae on tergite VII. **Symphysomery.**

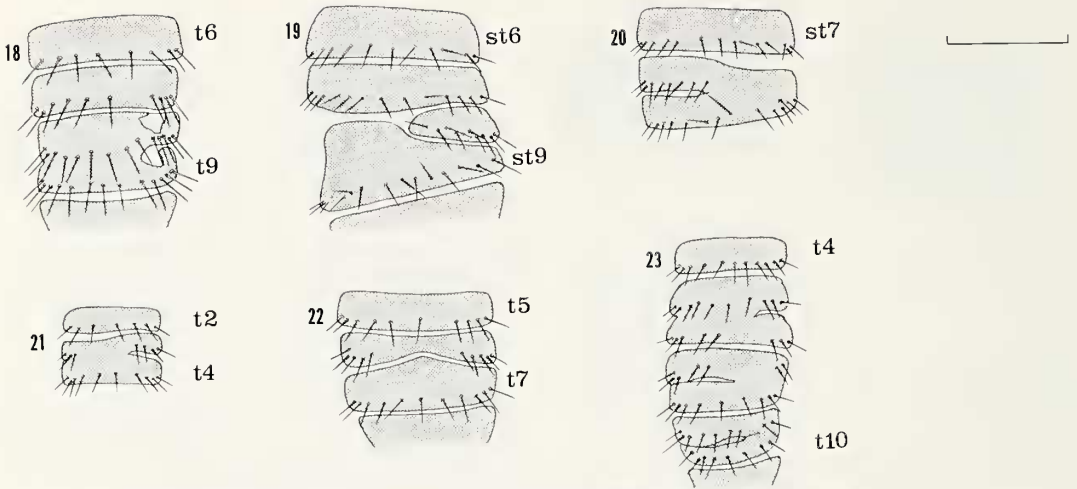
Male (Fig. 18). Tergites VIII and IX are fused together. In addition, small parts of tergites VIII and IX are missing on the right, hence the irregular setation on tergites VII-IX. **Partial atrophy and symphysomery.**

Female (Fig. 19). Part of sternite VIII is completely absent. Sternite IX is enlarged on the left and fills the space where the missing part of sternite VIII would otherwise be developed. The setae on the remaining part of sternite VIII are missing, and their position is altered in relation to normal specimens. **Hemimery and sternite enlargement.**

Male (Fig. 20). Sternites VIII and IX are fused from the midline to the right side; hence, the setae are missing on the right part of sternite VIII. **Symphysomery.**



Figures 11-17.—*Roncus* aff. *lubricus* (A), from Obrež, near Belgrade, Yugoslavia. Scale line = 0.5 mm. 11. - tergites I-IV, male; 12. - tergites I-V, male; 13. - tergites I-VI, male; 14. - tergites I-III, male; 15. - tergites I-III, male; 16. - tergites V-VIII, male; 17. - tergites VI-VIII, male.



Figures 18-23.—*Roncus* aff. *lubricus* (A), from Obrež, near Belgrade, Yugoslavia. Scale line = 0.5 mm. 18. - tergites VI-IX, male; 19. - sternites VI-IX, female; 20. - sternites VII-IX, male; 21. - tergites II-IV, tritonymph; 22. - tergites V-VIII, tritonymph; 23. - tergites IV-X, tritonymph.

Tritonymph (Fig. 21). Tergites III and IV are almost completely fused. As a result of this malformation, the setation of tergite III is altered (the mid-region of this sclerite is devoid of setae).

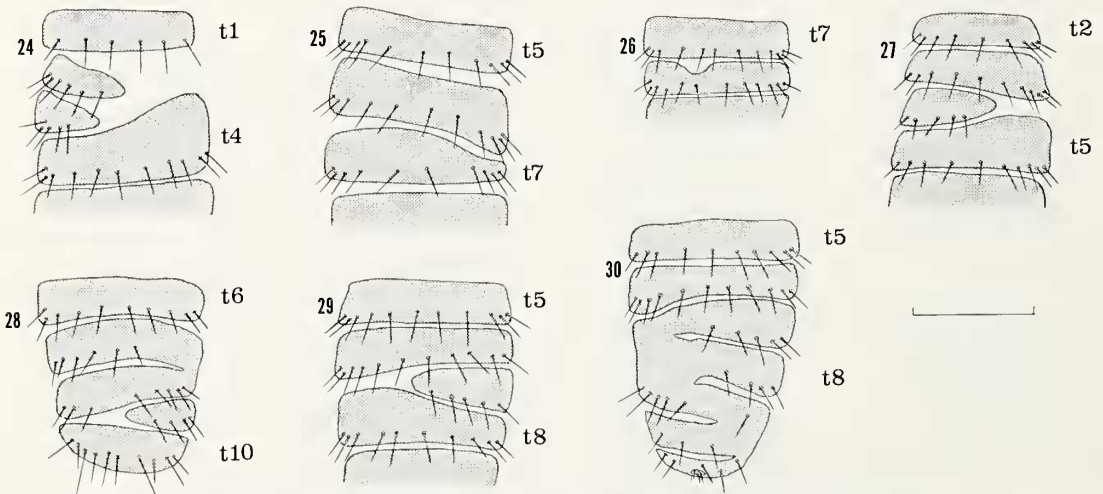
#### Symphysomery.

Tritonymph (Fig. 22). The posterior mid-region of tergite VI is atrophied; hence, the setae are missing in this area. In addition, tergite VII is enlarged anteriorly to fill the space left vacant by the tergite VI. **Partial atrophy and tergite enlargement.**

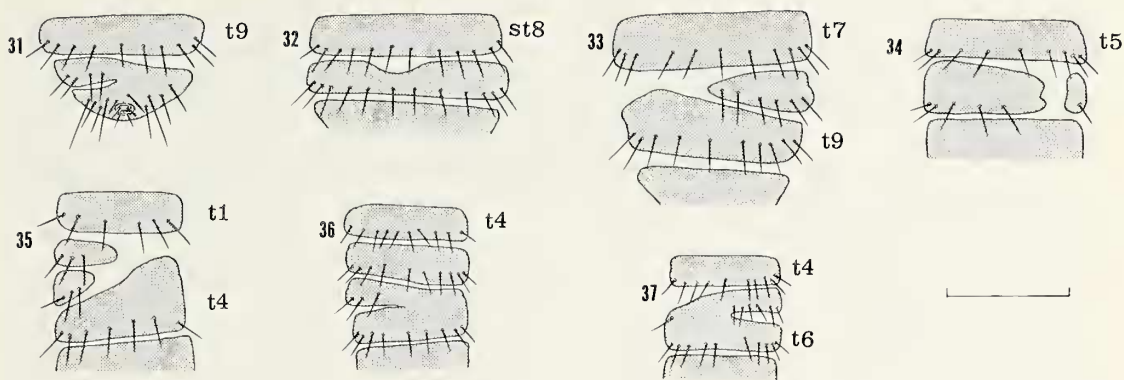
Tritonymph (Fig. 23). The tergal anomalies affect six tergites. Tergites V and VI are fused in the middle and on the left; tergites VII and VIII are fused on the right, as are tergites IX and X. As a consequence, the mid-regions of tergites VI and VII lack setae. **Multiple symphysomery.**

#### *Roncus* aff. *lubricus* (B)

**Village of Asanovac.** - Female (Fig. 24). In this specimen, right sclerite halves are missing on tergites II and III. The right anterior part of ter-



Figures 24-30.—*Roncus* aff. *lubricus* (B), from Asanovac, near Žitoradja, Yugoslavia. Scale line = 0.5 mm. 24. - tergites I-IV, female; 25. - tergites V-VII, female; 26. - tergites VII, VIII, male; 27. - tergites II-V, male; 28. - tergites VI-X, male; 29. - tergites V-VIII, male; 30. - tergites V-XI, male.



Figures 31-37.—*Roncus* aff. *lubricus* (B), from Dubova, near Žitoradja, Yugoslavia. Scale line = 0.5 mm. 31. - tergites IX-XI, female; 32. - sternites VIII, IX, female; 33. - tergites VII-IX, female; 34. - tergites V, VI, female; 35.- tergites I-IV, male; 36. - tergites IV-VII, tritonymph; 37. - tergites IV-VI, tritonymph.

gite IV is enlarged to fill part of the space left vacant in tergites II and III. **Multiple hemimery and tergite enlargement.**

Female (Fig. 25). Tergite VII is reduced in size in its anterior part on the right; hence, tergite VI is slightly enlarged posteriorly to fill the space where the missing part of tergite VII would otherwise be found. **Partial atrophy and tergite enlargement.**

Male (Fig. 26). The small anterior part of tergite VIII is missing. **Partial atrophy.**

Male (Fig. 27). Right part of tergite IV is missing. Tergites III and V are enlarged and fill the space where the missing part of tergite IV would otherwise be found. **Hemimery and tergite enlargement.**

Male (Fig. 28). Left part of tergite IX is missing. Tergites VII and VIII are fused on the right. As a consequence of these anomalies, the distribution of setae on tergites VII-IX is altered in relation to normal individuals. **Hemimery and symphysomery.**

Male (Fig. 29). The left half of tergite VII is missing. Tergite VI is enlarged posteriorly, and tergite VIII is enlarged anteriorly. **Hemimery and tergite enlargement.**

Male (Fig. 30). The tergal anomalies affect six tergites. Tergites VII-XI are fused (tergites VII-IX on the left and tergites IX-XI on the right). In addition, tergite VI is enlarged posteriorly on the left. As a consequence of these anomalies, the setation of tergites VII-XI is drastically altered. **Tergite enlargement and multiple symphysomery.**

**Village of Dubova (Ravnište) – Female (Fig. 31).** Tergites X and XI are fused on the right. The distribution of setae on tergite X is altered

(**symphysomery**). The mid-anterior part of sternite IX is also missing (Fig. 32; **partial atrophy**).

Female (Fig. 33). A deficiency is found in tergite VIII as manifested by the absence of the left part. The adjacent region of tergite IX is enlarged and partially fills the gap left by the missing half of tergite VIII. **Hemimery and tergite enlargement.**

Female (Fig. 34). Part of tergite VI on the right is missing. **Partial atrophy.**

Male (Fig. 35). The right parts of tergites II and III are missing. The adjacent part of tergite IV is enlarged anteriorly to fill part of the space left vacant in tergites II and III. The number and disposition of setae on tergites II and III are altered. **Multiple hemimery and tergite enlargement.**

Tritonymph (Fig. 36). Tergites VI and VII are fused on the right, hence the unequal distribution of tergal setae. **Symphysomery.**

Tritonymph (Fig. 37). Tergites V and VI are fused on the left. As a consequence of this anomaly, the distribution and number of setae are changed in relation to normal specimens (Zlatković 1989). An isolated seta is present on the left side of tergite V. **Symphysomery.**

The numbers of anomalies of males and females of *R. aff. lubricus* (A) and (B) were not significantly different ( $\chi^2$  test,  $P > .05$ ) for any of the three locations. Thus, these data offer no confirmation that a sex-linked inheritance of abdominal deficiencies exists in the analyzed species.

Comparison of the teratological variation in the analyzed species of *Roncus* clearly showed that this phenomenon was particularly marked in *R. aff. lubricus* (A) (Table 1), less so in *R. aff.*

Table 3.—Abdominal abnormalities in different sexes and growth stages of *Roncus* aff. *lubricus* (A) and (B) from three sites. M = males, F = females, T = tritonymphs, D = deutonymphs, P = protonymphs, OBR = Obrež, ASA = Asanovac, DUB = Dubova.

Species	Site	Sex/instar					Total	% abnormal males	% abnormal specimens
		M	F	T	D	P			
<i>R. aff. lubricus</i> (A)	OBR	9	11	3	—	—	23	39.3	0.7
<i>R. aff. lubricus</i> (B)	ASA	5	2	—	—	—	7	71.4	0.6
<i>R. aff. lubricus</i> (B)	DUB	1	3	2	—	—	6	16.7	1.1
	Total	15	16	5	—	—	36		
	Mean							42.4	0.8

*lubricus* (B) from Asanovac, and the least in *R. aff. lubricus* (B) from Dubova (Table 1) and *R. lubricus* (Čurčić 1989b, see Table 5). Such obvious differences, or the different degrees of teratological variation, may be due to different frequencies of some segmental anomalies or sample sizes (i.e., too small to give a detailed picture of the whole range of teratological variability of the species). Another explanation for the unequal variation of teratological phenomena might be the different susceptibility of various pseudoscorpion populations to the factors which cause malformations. That both assumptions may be correct is further supported by the similar unequal frequency of different anomalies in other genera and species of the Neobisiidae, and particularly of the species of the genus *Neobisium* (Čurčić 1989a, b).

## DISCUSSION

Postembryonic instars of each species were found in each of the localities (Table 2), with the absence of protonymphs of *R. aff. lubricus* (A) from Obrež and Dubova, and deutonymphs and protonymphs of *R. aff. lubricus* (B) from Asanovac.

In the more frequently occurring species, *R. aff. lubricus* (A), 23 abnormal specimens were noted (Table 3), while in *R. aff. lubricus* (B), the numbers of aberrant examples in different samples ranged from six to seven (Table 3). The majority of abnormal specimens were adults, with the exception of three tritonymphs of *R. aff. lubricus* (A) and two tritonymphs of *R. aff. lubricus* (B) (Table 3).

In *R. aff. lubricus* (A) from Obrež we found that the frequency of anomalies of the abdominal sclerites is 0.7%, whereas in *R. aff. lubricus* (B) it varies from 0.6% to 1.1%, depending on the

site. In general these values correspond to the frequency of anomalies in *R. lubricus* from other sites, as noticed elsewhere by Čurčić (1989b). The highest percentage of these aberrations has been noted in the sample of *R. aff. lubricus* (B) from Dubova, and the lowest in the sample of the same species from Asanovac. It is pertinent to note that the frequency of segmental anomalies in *R. aff. lubricus* (A) and (B) is essentially similar in different populations.

The analysis of the samples of *R. aff. lubricus* (A) and (B) showed that teratological variation of the abdominal sclerites was confined mostly to adults [86.9% in *R. aff. lubricus* (A), and from 66.6% to 100% in *R. aff. lubricus* (B)].

The deficiencies in abdominal sclerites of the species studied were variable. Thus, in *R. aff. lubricus* (A) as many as 11 different single or combined anomalies were noted. However, in *R. aff. lubricus* (B) from Asanovac only four types of aberrations were found, while in the same species from Dubova we noted the existence of three kinds of malformations. Among the reasons for the unequal distribution of anomalies in different samples might be the inappropriate sample size or the unequal susceptibility to the factors causing such aberrations.

The analysis of the samples of *R. aff. lubricus* (A) and (B) revealed that malformations of abdominal sclerites are confined mainly to adults. It is also evident that tergal anomalies are more frequent than those affecting the sternites.

The sex-linked distribution of segmental anomalies varies considerably, depending on the sample studied. Thus, in *R. aff. lubricus* (A) only 39.3% of males were aberrant; in *R. aff. lubricus* (B), however, the percentage of abnormal males varied from only 16.7% (Dubova) to as high as 71.4% (Asanovac). However, Čurčić (1989b) reported an incidence of 80.0% of aberrant males



in *R. lubricus*, and 50–100% aberrant males in different species of *Neobisium* (with the sole exception of *N. sylvaticum*, where the frequency of abnormal males was only 16.7%). One possible explanation is that the genesis of abdominal deficiencies is connected either with male- or female-linked inheritance, as noted elsewhere by Čurčić and Dimitrijević (1985, 1986).

The study of the relative distribution of segmental anomalies in the adult and tritonymph stages of *R. aff. lubricus* (A) and (B), as compared to the same feature in different species of *Neobisium* and *Roncus* (Čurčić 1989a, b) revealed the following: (1) hemimery, if present, is restricted to the anterior part of the abdomen, (2) atrophy is found mostly in the anterior abdominal region, although it may occur also in the posterior region, as already noticed by Čurčić (1989b), (3) symphysomery develops in the anterior, median and posterior sclerites, whereas in *Neobisium* it was noted that this malformation is present mainly in the central region of the abdomen (Čurčić 1989b), (4) the relative position of sclerite enlargement is often correlated with the presence and relative position of partial atrophy or hemimery. Hence, the combination of these anomalies develops both in the anterior and in the posterior abdominal parts. On the other hand, combined symphysomery and sclerite enlargement have been noted in the posterior, while other combinations of different aberrations are confined to the anterior sclerites. Therefore, the evidence [furnished elsewhere by Čurčić (1989a, b)] obtained for *R. aff. lubricus* in general confirms the data for *Neobisium* and *Roncus* species, (5) helicomery (combined with other malformations) is confined to the anterior sclerites. It is noteworthy that Čurčić and Dimitrijević (1986) have found that the single case of helicomery was restricted to the posterior region of the abdomen.

In each analyzed sample, segmental deficiencies are unequally distributed between representatives of different sexes. In *R. aff. lubricus* (A) and *R. aff. lubricus* (B) from Dubova, the percentage of anomalous females was higher than that of aberrant males. Only in *R. aff. lubricus* (B) from Asanovac was the frequency of aberrant males higher than that of females. In the majority of *Neobisium* species which were analyzed by Čurčić (1989b), the percentage of anomalous males was found to be higher than that of aberrant females.

In most cases, the development of sclerite anomalies causes simultaneous malformations in the setation of tergites and sternites. In other words, changes in the number, size and disposition of setae result from deficiencies affecting either parts of or whole sclerites.

It is already known that the majority of the abdominal anomalies occur during the transformation of the tritonymphs into adults. A considerably smaller number of specimens become anomalous when transforming from the deutonymph into tritonymphs (Čurčić, Krunić and Brajković 1983; Čurčić 1989a, b; Legg and Jones 1988). The causes of the lower frequency of aberrations in earlier instars are unknown.

A number of anomalies are likely to be the result of earlier mechanical injuries, at the juvenile or the adult stage. The most frequent consequence of such lesions, apart from alteration of setation, is the depigmentation of certain areas of the sclerites. Such specimens are viable and fully capable of reproduction.

Although the malfunction of the hormonal system, as well as some environmental factors, might be causes of various aberrations in abdominal sclerites, it seems likely that genetic factors can also give rise to such aberrations (Gehring 1985). Among them, the factors of metamerization should be especially mentioned. There are a number of findings which would support this view: the constancy of teratological variation in wild populations, a comparatively similar incidence in percentages of abnormal specimens in different populations, the noted degree of qualitative diversity and specific features of the distribution of different aberrations at various growth stages and in both sexes in each particular species.

#### ACKNOWLEDGMENTS

We are grateful to Zoran Ivković (Belgrade) for his useful comments on some statistics used in this paper. We are also grateful to Sigurd Nelson Jr. and Vincent F. Lee for the constructive criticism of the manuscript.

#### LITERATURE CITED

- Balazuc, J. 1948. La tératologie des Coléoptères et expériences de transplantation sur *Tenebrio molitor* L. Mem. Mus. Hist. Nat., Paris, 25:1–293.  
 Balazuc, J. 1967. Production expérimentale d'anomalies de segmentation chez *Mantis religiosa* L. Entomologiste, 23:45–50.

- Beier, M. 1955. Pseudoscorpionidea. S. African Anim. Life, 1:263-328.
- Chamberlin, J. C. 1949. New and little-known false scorpions from various parts of the world (Arachnida, Chelonethida), with notes on structural abnormalities in two species. American Mus. Novitates, 1430:1-59.
- Ćurčić, B. P. M. 1980. Accidental and teratological changes in the family Neobisiidae (Pseudoscorpiones, Arachnida). Bull. British Arachnol. Soc., 5: 8-15.
- Ćurčić, B. P. M. 1983. New cavernicolous pseudoscorpions from Serbia. Rec. Rapp. Com. Karst Speleol., Ed. Spec. Acad. Serbe Sci. Arts, Presid., 1:135-150.
- Ćurčić, B. P. M. 1988. Cave-dwelling pseudoscorpions of the Dinaric Karst. Acad. Sci. Art. Slov., Cl. IV, Hist. Nat., Opera, 26, Inst. Biol. Ioannis Hadži, 8:1-192.
- Ćurčić, B. P. M. 1989a. Segmental anomalies in some European Neobisiidae (Pseudoscorpiones, Arachnida) - Part I. Acta Arachnol., 37:77-87.
- Ćurčić, B. P. M. 1989b. Segmental anomalies in some European Neobisiidae (Pseudoscorpiones, Arachnida) - Part II. Acta Arachnol., 38:1-10.
- Ćurčić, B. P. M., & R. N. Dimitrijević. 1982. On abnormalities of abdominal segmentation in *Neobisium carpaticum* Beier (Neobisiidae, Pseudoscorpiones, Arachnida). Revue Arachnol., 4:143-150.
- Ćurčić, B. P. M., & R. N. Dimitrijević. 1984. An abnormal carapaco-abdominal junction in *Neobisium carpaticum* Beier, 1934 (Neobisiidae, Pseudoscorpiones). Arch. Sci. Biol. Belgrade, 36:9P-10P.
- Ćurčić, B. P. M., & R. N. Dimitrijević. 1985. Abdominal deficiencies in four species of the Neobisiidae (Pseudoscorpiones, Arachnida). Revue Arachnol., 6:91-98.
- Ćurčić, B. P. M., & R. N. Dimitrijević. 1986. Abnormalities of carapacal and abdominal segmentation in *Neobisium* Chamberlin (Neobisiidae, Pseudoscorpiones). Actas X Congr. Int. Aracnol., Jaca/España, 1:17-23.
- Ćurčić, B. P. M., & R. N. Dimitrijević. 1988. Segmental deficiencies in some Neobisiidae (Pseudoscorpiones, Arachnida). TUB-Dokument. Kongr. Tagungen, XI Europ. Arachnol. Coll., Berlin, 1:89-97.
- Ćurčić, B. P. M., M. D. Krunić, & M. M. Brajković. 1981. Further records of teratological changes in the Neobisiidae (Arachnida, Pseudoscorpiones). Bull. British Arachnol. Soc., 5:280-284.
- Ćurčić, B. P. M., M. D. Krunić, & M. M. Brajković. 1983. Tergal and sternal anomalies in *Neobisium* Chamberlin (Neobisiidae, Pseudoscorpiones, Arachnida). J. Arachnol., 11:243-250.
- Dimitrijević, R. N. 1985. Patomorfološka analiza promena u segmentaciji abdomena kod nekih predstavnika porodice Neobisiidae (Pseudoscorpiones, Arachnida). M. Sc. Thesis, University of Belgrade. 72 pp.
- Dimitrijević, R. N. 1990. Neka obeležja postembrionalnog razvića i teratoloških promena kod pseudoskorpija iz porodica Chthoniidae i Neobisiidae (Pseudoscorpiones, Arachnida). Ph. D. Thesis, University of Belgrade. 241 pp.
- Gabbutt, P. D., & M. Vachon. 1963. The external morphology and life history of the pseudoscorpion *Chthonius ischnocheles* (Hermann). Proc. Zool. Soc. London, 140:75-98.
- Gardini, G. 1983. Redescription of *Roncus lubricus* L. Koch, type-species of the genus *Roncus* L. Koch 1873 (Pseudoscorpionida, Neobisiidae). Bull. British Arachnol. Soc., 6:78-82.
- Gehring, W. J. 1985. Homeotic genes, the homeobox and the genetic control of development. Cold Spring Harbor Symp. Quant. Biol., 50:243-251.
- Gilbert, O. 1952. Three examples of abnormal segmentation of the abdomen in *Dactylochelifer latreillei* (Leach), (Chelonethi). Ann. Mag. Nat. Hist., 5:47-49.
- Gupta, A. P. 1979. Arthropod phylogeny. Van Nostrand-Reinhold Co., New York, 762 pp.
- Hadži, J. 1930. Prirodoslovna istraživanja sjevernodalmatinskog otočja. I. Dugi i Kornati. Pseudoscorpiones. Prirod. istr. Kralj. Jugosl., 16:65-79.
- Hadži, J. 1937. Pseudoscorpioniden aus Südserbien. Bull. Soc. Sci. Skoplje, 17/18:13-38 and 151-187.
- Kästner, A. 1927. Pseudoscorpiones. Biologie Tiere Deutschlands (Berlin), 18:1-68.
- Legg, G., & R. E. Jones. 1988. Pseudoscorpions (Arthropoda; Arachnida). Keys and notes for the identification of the species. The Linnean Soc. London. Synopses British Fauna (N. S.), 40:1-159.
- Pedder, I. J. 1965. Abnormal segmentation of the abdomen in six species of British pseudoscorpions. Entomologist (London), 98:108-112.
- Weygoldt, P. 1969. The biology of pseudoscorpions. Harvard University Press, Cambridge. xiv + 145 pp.
- With, C. J. 1905. On Chelonethi, chiefly from Australian Region, in the collection of the British Museum, with observations on the "coxal sac" and some cases of abnormal segmentation. Ann. Mag. Nat. Hist., (7)15:94-143.
- Zlatković, M. R. 1989. Segmentalne anomalije kod pseudoskorpija *Roncus* i *Neobisium* (Pseudoscorpiones) iz okoline Žitoradje. B. Sci. Thesis, University of Belgrade. 42 pp.

*Manuscript received March 1991, revised May 1991.*